

A Systematic Approach to Dento-Facial Smile Evaluation Using Digital Photography and a New Photographic View



Jose-Luis Ruiz,
DDS

Although many experts have described the individual aspects and parameters for a dento-facial evaluation, a systematic approach to managing this information needs to be implemented. This will ensure consistent results and avoid the realization, after finishing a case, that facial parameters were overlooked, resulting in teeth that look great in the retracted view but don't enhance the patient's facial features.

This article will describe a systematic approach to dento-facial aesthetic evaluation using 11 photographic views, an articulated cast, and a form to help organize the available data (Dento-Facial Esthetic Diagnosis [DFD] form) and enable a step-by-step, systematic evaluation of the dento-facial parameters. A new photographic view, "conversational tooth reveal," will also be introduced.

bers of the aesthetic team (restorative dentist, specialist, dental technician) and the patient.

A comprehensive dento-facial evaluation and smile design can be divided into 4 areas: (1) dento-facial aesthetics—the evaluation of teeth as they relate to other facial structures, and the overall facial symmetry that is influenced by teeth; (2) group aesthetics—the evaluation of teeth as a group, independent of other facial structures; (3) gingival aesthetics—the evaluation of the soft tissue surrounding and framing the teeth; and (4) tooth aesthetics—the evaluation of the individual characteristics of the teeth. This article will discuss dento-facial aesthetics only.

THE AESTHETIC-DRIVEN DIAGNOSIS RATIONALE

Any time we may be considering an aesthetic oral rehabilitation that includes more than 4 teeth, we should consider starting with a dento-facial smile evaluation and design. The primary goal of this is to achieve an aesthetic and harmonious dento-facial treatment outcome; this will be followed by the engineering of the occlusal scheme to ensure stability and longevity. This concept is similar to the approach used when constructing a new building or doing extensive remodeling; it should always start with the architectural design. The architect's first goal is a beautiful and functional building. Subsequently, the engineer designs the structural stability and longevity of the building.

The first step in the evaluation and design is gathering the appropriate records, which include a full set of periapical x-rays, panoramic x-ray, 6-point periodontal charting, and articulated casts mounted using a face-bow and a semiadjustable articulator with specific features for aesthetic evaluation and design (Panadent). A full set of photographic views is indispensable; good quality photographs can be acquired using a simple point-and-shoot digital camera (Canon G5). This system requires 11 photographic views: 1:10 full-face smiling front view; 1:10 side view; 3 nonretracted 1:2 front, right, and left smiling views; 3 retracted 1:2 front, right, and left views; and maxillary and mandibular 1:2 occlusal views. (These views are taken using the American Academy of Cosmetic Dentistry

Figure 1. The Dento-Facial Esthetic Diagnosis (DFD) form, used to evaluate data methodically.

Figure 2. Needed referrals are immediately recorded as the different dento-facial parameters are evaluated.




Figure 3. Evaluation of midline and incisal plane, using the full-face view.

To avoid making beautiful teeth that don't fit our patient's faces, or finishing our aesthetic treatment and later regretting we didn't notice something that could have enhanced our patient's aesthetic appearance and satisfaction, organized data gathering and processing is necessary.

THE DENTO-FACIAL EVALUATION

When our patients come to us searching for aesthetic improvements, as dental professionals we immediately start to look at teeth and gums, as we have the techniques to repair and beautify them. We may even take retracted pictures and show them to our colleagues for diagnostic consultation or to present our great results. On the other hand, our patients are less concerned about how teeth and gums look. They are more concerned about their smile and the way it enhances their face... they look at the big picture.

In recent years more attention has been placed on the facial evaluation.¹⁻⁴ A popular approach to record and evaluate the dento-facial structures has been the use of photographic views to assess tooth position in relation to lips and face. This gives us the opportunity to review crucial information even in the absence of the patient. It is also an excellent way to communicate amongst the mem-

A Systematic Approach...

continued from page 83

Figure 6. This view can also be used to confirm or assess lower-third symmetry. As we know, the teeth support the lips and lower third of the face, and a restorative decision can have a dramatic effect on the patient's appearance. If the clinician or the patient notices excessive protrusion or retrusion, a mark will be made on the drawing. Then a decision has to be made as to whether the correction can be made with restora-

tive dentistry alone, or if a referral to a specialist (orthodontist or oral surgeon) will be appropriate.

The dentist who wishes to provide patients with excellent dento-facial diagnosis and treatment must accept the responsibility to respect, understand, and manipulate the described facial features in the patient's best interest. Often the solutions will include using a multidisciplinary approach, including restorative dentistry, orthodontics, periodontics, and orthognathic surgery, or a combination of these.

The third view is the unretracted smile close-up 1:2. This view allow us to evaluate for parameters f

(smiling tooth show³), g (buccal corridor³), h (gingival show; although it involves the gingiva, it is considered in this category because it is measured in relation to other facial structures¹¹), i (incisal plane), and j (incisal plane to lower lip¹; Figure 8). If any of the parameters is unacceptable to the patient or the clinician, then we will mark the form and make a notation as to whether we are able to correct the unacceptable parameter with our restorative dentistry, or if a referral to the specialist is required, as previously described.

1. DENTO-FACIAL ESTHETICS			
a) Occ. Plane: _____	d) Lip Protrude: _____	g) Tooth Show (Smile): _____	i) Incisal Plane: _____
b) Midline: _____	e) L. 3rd Golden P: _____	h) Buccal Corridor: _____	j) Incisal Plane T Lip: _____
c) Symmetry: _____	f) Ging. Show: _____	k) Conversational TS: _____	

Figure 6. A simple way to record referrals and the ultimate goal for such referral.

Kois Dento-Facial Analyzer™

Combining Esthetics & Function!

- Quality
- Simplicity
- Predictability

Panadent (800) 368-9777

www.panadent.com • info@panadent.com

U.S. and Foreign Patent Pending

FREEinfo, circle 56 on card

Figure 7. This view can also be used to confirm or assess lower-third symmetry. As we know, the teeth support the lips and lower third of the face, and a restorative decision can have a dramatic effect on the patient's appearance. If the clinician or the patient notices excessive protrusion or retrusion, a mark will be made on the drawing. Then a decision has to be made as to whether the correction can be made with restorative dentistry alone, or if a referral to a specialist (orthodontist or oral surgeon) will be appropriate.



Figure 7. The use of Ricketts e-line for lip profile evaluation.

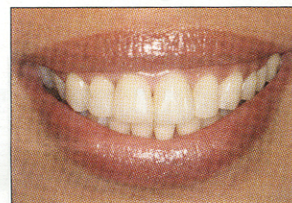

Figure 8. The unretracted natural smile used to evaluate tooth show, buccal corridor, gingival show, and incisal plane to lower lip plane.

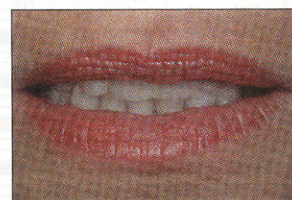

Figure 9. New "conversational tooth reveal" photographic view records the amount of tooth reveal or show during a conversation.

CONVERSATIONAL TOOTH REVEAL

When assessing the appropriate amount of tooth reveal or show, the most recommended photographic views have been the full-smile view and the lip at rest position.^{5,7} It could be contended that while the full-smile view is an indispensable view, lip at rest is probably not as important, because people look at the mouth primarily when we talk, smile, or laugh. For this reason tooth position at rest is probably of no great importance. Assessing conversational tooth show, however, is more significant to achieve an ideal dento-facial result. The problem is that trying to assess how much tooth people show when they talk is somewhat subjective and difficult, and it varies depending on what words they are saying. In addition, it requires that we be observant when our patients are speaking, and record in our brain if they show enough teeth or how much of the teeth they actually show.

Searching for a way to record "conversational tooth reveal" has led me to the use of the good old *sixty-six* sound and a new photographic view. As we know, the sound *S* is made when air escapes between our teeth, when they are almost touching and our lips are slightly open. The *S* sound is one of the most common in the vocabulary, which means during a conversation, even a short one, the patient will make this sound, and this will become part of the "conversational tooth reveal." In addition, this sound requires that we stretch our lips, and this gives a maximum tooth reveal in the absence of a smile. This photo-

graphic view is taken asking the patient to say "sixty-six" multiple times. The camera will be framed and focused. While the patient repeats "sixty-six," the picture is taken, and the conversational tooth reveal is recorded (parameter *k*; Figure 9). The amount of tooth that should be revealed during a conversation varies among patients depending on age and sex,¹² but it is absolutely indispensable that the patient shows at least the tips of the teeth when conversing. Otherwise the patient appears to have no teeth, which ages the face.

ADDITIONAL RECORDS

In this article we have discussed the facial aesthetic evaluation; this should be followed by reviewing group aesthetics, gingival aesthetics, and individual tooth aesthetics, which will finish the aesthetic evaluation. The oc-



Figure 4. Evaluation of the lower facial third, using the Golden Proportion ruler.

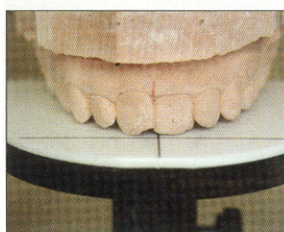


Figure 5. Cast mounted using the Kois face-bow and adjustable mounting platform (Panadent), used as adjunctive data for dento-facial evaluation. Later this cast will be replicated and cross-mounted to be used for the wax-up.

op a form similar to the one described in this article or may contact the author for a free copy.) The secret to excellent patient treatment acceptance and patient satisfaction is listening to the patient's needs and developing our diagnosis around the patient's concerns and goals. It is crucial to make good notes regarding the patient's original aesthetic goals and overall desires. Our forms should have ample space for patients to write their goals and concerns, and for us to systematically record them. This is also why, during the record visit, it is desirable to allow time for the patients to look at the different photographic views and spend a few minutes with them, allowing them to verbalize what they see on the pictures and what they like and dislike about them.

DENTO-FACIAL AESTHETICS

Dento-facial aesthetics is the evaluation of teeth as they relate to other facial structures and the overall facial symmetry that is influenced by teeth. Following the format of the DFD form, section 1 is evaluation of dento-facial aesthetics. There are 4 drawings that represent 4 photographic views necessary to evaluate the 11 most important parameters of dento-facial aesthetics in this system. Next to them is a referral box; each parameter is evaluated, and notes on needed referrals are made at that moment (Figure 2).

The first photographic view to be evaluated is the smiling full-face frontal 1:10 view. This photograph allows us to evaluate 4 parameters: (a) midline; (b) occlusal plane⁷; (c) facial symmetry⁷; and (d) facial lower-third symmetry using the Golden Proportion Principles^{8,9} (Figures 3 and 4). As an adjunct confirmation, we may use properly mounted casts. Later these casts will also be used to communicate with the laboratory technician and other members of the aesthetic team and to fabricate ideal wax-ups using the design developed (and using the form as a guide; Figure 5). All of the parameters described in this article have been extensively explained in the literature, with the exception

of "conversational tooth reveal." If any of these parameters are outside the acceptable limits, then a mark is made in the corresponding drawing and a notation on the appropriate line. At that

point a decision is made as to whether it is possible to correct the discrepancy with restorative dentistry; if not, a note is made regarding referral to the appropriate specialist. For example, if the prob-

lem is an extreme midline discrepancy, not reparable with restorative dentistry, then a note to refer the patient to an orthodontist for correction would read as fol-

continued on page 84

Your Practice Deserves the Best

Intraoral photography is an essential element of your business. And working with Calumet is an excellent way to guarantee that your photo needs are met with state-of-the-art gear, knowledgeable tech reps and affordable pricing.

We at Calumet have been assisting professionals like you for nearly 70 years. Contact us today to learn more about how we can work together to better your business.



KIT PRICE
\$2399⁰⁰

Canon
EOS 20D
DIGITAL



The **8.2MP CANON 20D DIGITAL SLR CAMERA KIT** is ideal for dental or medical office/surgery use. Document wounds or capture your garden with the macro 100mm lens and macro ring light.

Kit Includes:

- Canon 20D Camera
- Canon MR-14EX Macro Ring Lite
- Canon 100mm Macro Lens
- Calumet BP-511 LI-Ion Battery
- Calumet 6-Hr. Charger w/4-AA 2500 Batteries
- Calumet 4-AA 2500mah Batteries
- Lexar USB 2.0 CF Card Reader
- 512MB CF Card
- Pelican 1500 Case w/Dividers

CALUMET
PHOTOGRAPHIC
calumetphoto.com

1.800.CALUMET (225.8638) U.S. toll free ordering
calumetphoto.com For on-line ordering, more information
or more dental kit listings

- New York, NY 212.989.8500 • Cambridge, MA 617.576.2600
- Philadelphia, PA 215.399.2155 • Chicago, IL 312.440.4920
- Bensenville, IL 630.860.7458 • San Francisco, CA 415.643.9275
- Los Angeles, CA 323.466.1238 • Santa Barbara, CA 805.965.7053
- Santa Ana, CA 714.285.0143 • San Diego, CA 760.737.6002

FREEinfo, circle 55 on card

general guidelines.⁵) Another key view is a new photographic view and concept, the "conversational tooth reveal," which will be described later in this article.

A well-trained dental assistant may take these photographs and study casts.⁶ The pictures are then loaded into the computer and shared with the patient. During the record-taking visit, the dentist will only be involved in taking the face-bow record using the aesthetic Kois dento-facial analyzer (Panadent), taking the CR occlusal record, and reviewing the pictures with the patient, taking notes as the patient shares his or her opinions about the photos.

THE AESTHETIC-DRIVEN DIAGNOSIS FORM

In order to have consistency in the evaluation of the available data, it is desirable to have a form that guides us through the records and provides us a systematic way to review the photographs and make decisions as we evaluate them. The DFD form (Figure 1) helps organize this data. (The reader may devel-

clusion will then be evaluated using ideally mounted casts, and a functional evaluation and treatment plan will be developed. It goes without saying that during the initial visit, 6-point periodontal charting as well as a caries evaluation including radiographs were performed, which will be considered in the final treatment plan.

CONCLUSION

To avoid making beautiful teeth that don't fit our patients' faces, or finishing our aesthetic treatment and later regretting we didn't notice something that could have enhanced our patients' aesthetic appearance and satisfaction, organized data gathering and processing are necessary. This article has proposed a system using photographs and other records to simplify this complicated task. Also, the use of a new photographic view and concept is proposed. Armed with this well-organized and valuable information, and using a systematic and well-developed diagnosis and treatment plan, we can communicate to our patients our commitment to them, their aesthetic goals, and their overall dental well-being. This will naturally increase treatment acceptance and patient satisfaction. ♦

References

1. McLaren EA, Rifkin R. Macroaesthetics: facial and dentofacial analysis. *J Calif Dent Assoc.* 2002;30:839-846.
2. Ruiz JL. The psychology of a smile. *J Cosmet Dent.* 2003;9:58-59.
3. Morley J, Eubank J. Macroesthetic elements of smile design. *J Am Dent Assoc.* 2001;132:39-45.
4. Morr T. Understanding the esthetic

Dr. Ruiz is the course director of the USC Advanced Esthetic Dentistry Continuum and clinical instructor at the University of Southern California. He is a fellow of the AGD, associate instructor and mentor at PCC Utah (teaching with Dr. Gordon Christensen), and an independent evaluator of dental products for CRA. Dr. Ruiz has been practicing general dentistry in the Film Studio district of Los Angeles for more than 13 years, where he treats many stars and entertainers. His aesthetic makeovers have been featured on a number of television shows including NBC 4 News, ABC 7 *Vista LA*, and Channel 52 *Telemundo*, and he is regularly consulted on aesthetic dentistry. Dr. Ruiz lectures internationally and has published multiple papers on cosmetic dentistry and team leadership. He can be reached at (818) 558-4332 or ruiz@drruiz.com.

- evaluation for success. *J Calif Dent Assoc.* 2004;32:153-160.
5. Steel C, Behle C, Ballerino M, et al. *Photographic Documentation and Evaluation in Cosmetic Dentistry: A Guide to Accreditation Photography*. Madison, Wis: American Academy of Cosmetic Dentistry.
 6. Christensen GJ. *Data Collection by Auxiliaries* [videotape/DVD]. Provo, Utah: Gordon J. Christensen Practical Clinical Courses. Available at: <http://www.pccdental.com/cgi-bin/pcc/V1180.html>.
 7. Lee RL. Standardized head position and reference planes for dento-facial aesthetics. *Dent Today.* 2000;19:82-87.
 8. Ricketts RM. The biologic significance of the divine proportion and Fibonacci series. *Am J Orthod.* 1982;81:351-370.
 9. Mancuso A. Esthetic dentistry and the golden proportion. *Oral Health.* April 2004. Available at: http://www.dental-practicemgmt.com/issues/past_issues.asp. Accessed February 2006.
 10. Ricketts RM. A foundation for cephalometric communication. *Am J Orthod.* 1960;46:330-357.
 11. Chu SJ, Karabin S, Mistry S. Short tooth syndrome: diagnosis, etiology, and treatment management. *J Calif Dent Assoc.* 2004;32:143-152.
 12. Vig RG, Brundo GC. The kinetics of anterior tooth display. *J Prosthet Dent.* 1978;39:502-504.

**Quality Products
at Amazing Prices.
Case after Case.**

d-Sign®
Porcelain to Noble Crown



\$89⁹⁵
per unit
flat rate including metal

Select the
FIXED RESTORATION
OF YOUR CHOICE

PFM RESTORATIONS

Prices are flat-rate per unit, including metal

d-Sign® Porcelain to N.P. Alloy	\$73.95
d-Sign® Porcelain to Noble Alloy	\$89.95
d-Sign® Porcelain to High Noble Alloy	\$104.95
Captex™	\$109
Golden Gate™ (<i>Metal Occlusal add \$20</i>)	\$126

METAL-FREE RESTORATIONS

Prices are flat-rate per unit

Cercon™ Zirconia Crown & Bridges	\$115
IPS Eris® Crown & Bridges	\$109
IPS Empress® Esthetic Crown	\$99
Wolceram® Crown & Bridges	\$105

Send us your first case and receive a

25%
DISCOUNT!

Our Remake Percentage is less than 2.5...well below industry standard...and we offer
No Charge with our "No Fault" Remake Policy!

Our **QUALITY** SPEAKS FOR ITSELF!
"Since we opened our office we have tried several dental labs and have found Assured Dental to meet and exceed all of our dental lab needs. The work they do is of the highest quality and the customer service is wonderful. We recommend them to any dental office seeking to receive the best care out there."

Justin D. Simmons, DDS - Stacy L. Simmons, DDS
Canyon View Dental, PC - Hamilton, Montana

Please visit us at the CDA Meeting at booth #2457

Free Starter Kit...Call Today!

877.283.5351



936 SE Ankeny Street • Suite #1 • Portland, OR 97214-1300
503.283.5351 • 877.283.5351 • fax 503.283.5375

FREE STARTER KIT CALL 877-283-5351 or circle 57 on card