



dentalCEtoday.com

Go online to earn credit for reading this CE article.

Are Full-Coverage Crowns Overutilized?

Supragingival Partial-Coverage Designs As a First Option



Jose-Luis Ruiz,
DDS



Renee Kurtz,
DMD

INTRODUCTION

Independently of what dental material we choose to use, full crowns are destructive and, many times, unnecessary. A strong shift to all-ceramic crowns has been occurring in dentistry. However, any benefits of the new restorative materials are wasted when we use them in the same way we use older materials (such as PFMs). The full-coverage crown is still the most popular restoration in dentistry, and it is the authors' opinion that neither dentists nor patients are always better off with them. *CLINICIANS REPORT's* recent survey of dental laboratories (in the United States) show that only 2% of all restorations fabricated by laboratories are partial coverage onlays or veneers. In the anterior of the mouth, partial-coverage and bonded veneers are not just an aesthetic restoration, but should be used, whenever possible, instead of full crowns. The primary reason more clinicians don't perform more partial-coverage restorations is that they are unfamiliar with how to prepare and place these minimally invasive alternatives.

This article will discuss the rationale for minimally invasive supragingival adhesive

restorative dentistry, and present 2 clinical case examples showing some of the techniques used with this treatment concept.

Changing the Way We Practice Dentistry

The important benefits of supragingival restorative techniques first described by Ruiz and Christensen¹ have simplified bonded restorative procedures by intentionally keeping the restorative margins above the gingival. This can change the way we practice dentistry, making it easier and more predictable than traditional restorative techniques.

Advances in dental materials, along with better understanding and proper use of them, have enabled us to steer away from the aggressively prepared PFMs to more conservative and aesthetic nonmetal bonded restorations with predictable clinical success.² New materials require learning new techniques; failure to do so can result in improper use of materials and, eventually, failing restorations. However, when properly used, these new materials and techniques can improve clinical success and increase patient satisfaction.

Supragingival partial-coverage bonded restorations use a revolutionary approach to restorative dentistry, with a very intentional goal to keep the indirect restoration margins above the gingival as much as possible, thus making dentistry easier and better. There are some very important benefits to intentionally keep the restorative margins supragingival: healthier gingival tissues, better and easier restorative procedures, and more conservative tooth reduction are some of them.³ Performing supragingival dentistry is possible thanks to the new restorative materials available today, when used appropriately. Nevertheless, because traditional subgingival crown and bridge techniques are what most doctors were taught in dental school, after graduating, it becomes an everyday routine that then turns into a difficult habit to recognize and change.

Traditional Subgingival Full-Coverage Restorations

Because of the aesthetic demands of the public, the most popular indirect restorative procedure today is the full-coverage, tooth-colored crown. Recent surveys show that full crowns (mostly PFMs and full zirconia) are currently the most popular lab-fabricated restorations in the United States, accounting for 98% of all the indirect restorations placed.⁴ Both of the above full crowns are opaque (although more translucent zirconias are being introduced, they are still not as aesthetic as other all-ceramic alternatives) and often require a subgingival margin design to hide an unaesthetic restorative margin. Traditionally, dental schools and textbooks teach full-coverage techniques with the necessary step of placing the restorative margins below the gingival tissues to hide the potentially—and often—unaesthetic margin. The increase in difficulty and unpredictability that this routine procedure brings to the table is formidable. The first challenge is the need to prepare the subgingival margin atraumatically. When done correctly, this step requires that we first prepare an initial equigingival margin; then, retraction cord should be placed

continued on page 124

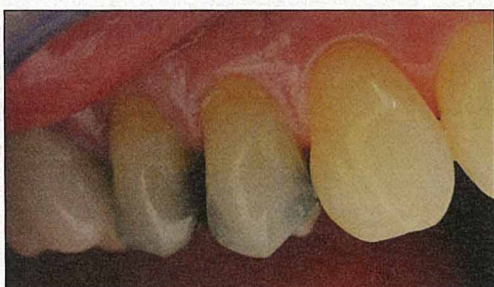

Figure 1. Buccal appearance of existing amalgams.

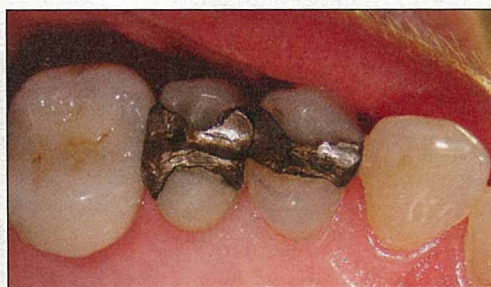

Figure 2. Observe the existing large amalgams with leakage and secondary caries.

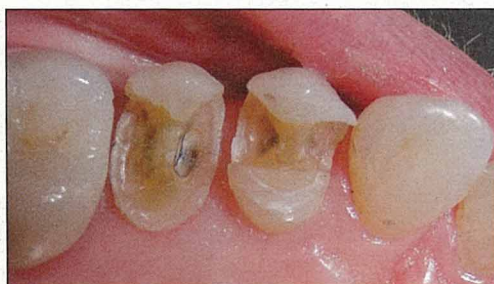

Figure 3. Tooth left after amalgam and caries removal with a 2.0 mm occlusal reduction of the lingual cusp.

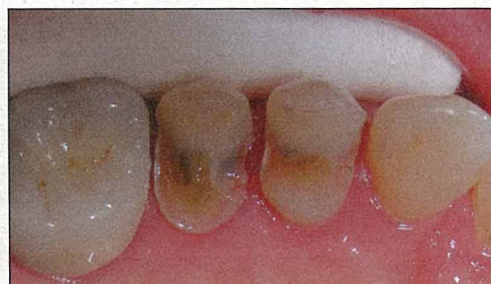

Figure 4. Buccal cusps have been repaired with undercuts and weakened enamel, restored with bonded composite.

Are Full-Coverage Crowns...

continued from page 122

in order to expose subgingival tooth structure so the margin can be placed below the gingival tissues; this is followed by a second cord to make a proper impression of the subgingival margin; and, of course, subgingival impressions carry their own challenges with them.⁵ If this is not difficult enough, the cementation procedure has its own challenges as well. First, it is not uncommon to see that, after the provisional is removed from this subgingival preparation, the gingiva is inflamed and bleeds easily. This is usually the consequence of a less-than-ideal provisional and less-than-ideal oral hygiene at home on the part of the patient. Fragile, bleeding gums pose difficulties in achiev-

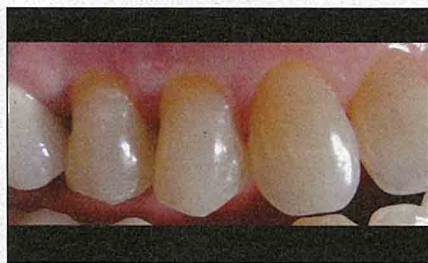

Figure 5. Buccal view of finished bonded onlays (IPS Empress [Ivoclar Vivadent]) with excellent aesthetic results.

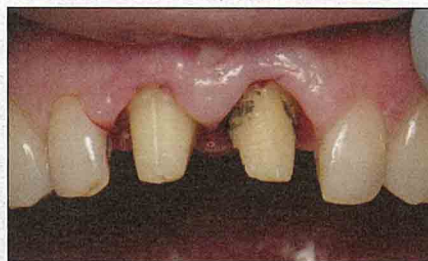

Figure 8. Observe the traditional tooth preparation required for full crowns.

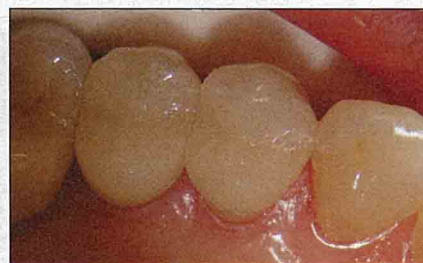

Figure 6. Finished bonded onlays.

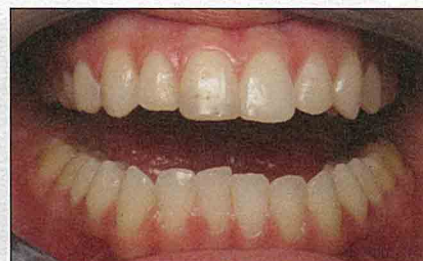

Figure 9. Pre-op of the maxillary centrals; the right central had the large fracture.

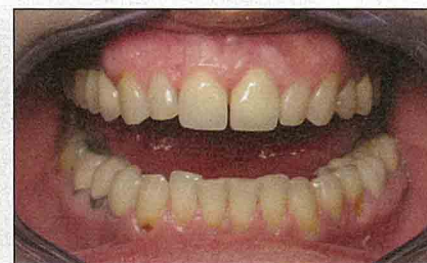

Figure 7. Two maxillary centrals restored with full crowns with subgingival margins (a different patient). Note the traditional unhealthy looking tissues.

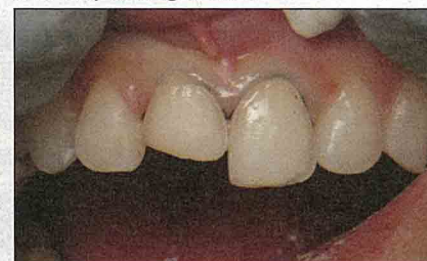

Figure 10. Observe the minimally invasive supragingival veneer preparations.

Supragingival restorations are not only friendlier to the tissues; they also preserve tooth structure....

ing hemostasis, a necessary step for isolation for proper cementation.

Unfortunately, the “tradition” of subgingival margin placement has continued with all-ceramic restorations. Subgingival margin placement is often used for bonded ceramic restorations like veneers, all-ceramic crowns, and even nonmetal onlays. By using subgingival margins with resin-bonded restorations, the difficulty levels of the techniques involved increase, and the important benefits of the restorations are lost. A major problem with this approach is that bonding materials and resin cements are intolerant to contamination. Controlling bleeding when subgingival margins are placed is one of the most difficult, stressful, and unpredictable things that we do. When we reflect on how difficult subgingival procedures are, it is easy to recognize that clinicians, who use these more aggressive preparation designs in situations where supragingival designs could be used, simply make their work more challenging and complicated.

Supragingival Partial-Coverage Bonded Restorations: Really Better?

Yes, but that is only possible by utilizing supragingival techniques, as described by the Ruiz,³ along with the proper use of adhesives, cements, and all-ceramic restorative materials. It is necessary to understand and maximize some of the inherent characteristics of all-ceramics.

For instance, *translucency* is an important characteristic when considering the use of these materials for partial coverage supragingival restorations. Translucency allows for an easier blend of the restoration to the tooth due to light transmission between the material and the tooth structure. The degree of translucency can vary dramatically, depending on the material. For example, pressed and layered feldspathic and leucite-reinforced porcelains tend to be very translucent; alumina and zirconia based restorations are always more opaque; and lithium disilicate is somewhere in the middle.

When using highly translucent feldspathic porcelain, layered or pressed, we can achieve a contact lens effect that causes a supragingival margin to disappear, thus contraindicating the placement of a subgingival margin. In heavy load areas and/or those areas out of the critical aesthetic zone (such as the second molars), we can choose to use stronger and less translucent all-ceramics like monolithic lithium disilicate or monolithic zirconia.

CASE EXAMPLES

Case 1: Minimally Invasive Supragingival Option

A patient presented to Dr. Kurtz with 2 very old amalgam restorations. Both had a history of significant leakage with secondary caries present (Figures 1 and 2).

It was decided to treat these teeth with indirect restorations because of the extent of the secondary caries leaving undermined cusps. After removing large, old restorations and extensive decay, we are often left with a deep prep and undercut cusps. Teeth like the second bicuspid in this case, when full-coverage is planned due to insufficient retentive axial walls, are often treated with intentional endodontic surgery followed by a post-and-core buildup before prepping for the crown. Devitalizing the tooth and aggressively removing sound tooth structure will only decrease the longevity of the tooth, not to mention the much higher costs incurred by the patient. Supragingival restorative techniques require that we intentionally preserve as much enamel/tooth structure as possible. In this case, we preserved as much tooth as possible (Figure 3). Some research shows that cusps can be reinforced with bonded composite resin.^{6,7} The benefits of preserving the buccal cusp are ideal aesthetics, much tooth preservation, enamel margins, and—if the occlusion is properly adjusted—the buccal cusp will never be in occlusal contact.

Bases/liners and/or composite resin dentin build-up materials can be used as a biological protection for deep areas and as dentin replacement underneath supragingival restorations (Figure 4). These base materials (Tetric EvoCeram [Ivoclar Vivadent]) can reduce the volume of an onlay to less than 4.0 mm, ensuring that one can adequately light cure the cement at placement of the final restoration, and fill in internal undercuts in an effort to retain nonworking cusps.

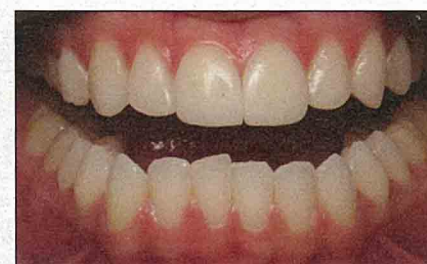

Figure 11. Finished maxillary central veneers. Note the excellent aesthetic blend at the margins, achieved by using the proper translucent porcelain (Noritake CZR Layered porcelain veneers [Kuraray America] by Burbank Dental Lab).

When margins are supragingival, the impression technique is easy and uncomplicated, and temporization (Structur 3 [VOCO America]) and cementation using Multilink (Ivoclar Vivadent) are accomplished predictably using adhesive techniques. In this case, the IPS Empress (Ivoclar Vivadent) placed were highly aesthetic, and the gingiva remained very healthy and unaffected by the operative procedures (Figures 5 and 6). Minimally invasive treatment techniques usually increase the chances of a longer life for teeth like these, especially since more extensive treatments were avoided.

Case 2: Anterior Supragingival Minimally Invasive Restorations

A female patient presented to Dr. Ruiz with a vital fracture in the right maxillary central that extended to almost the middle of the tooth. This tooth had been previously repaired with direct composite resin, but the patient was not happy with the final aesthetic results. In fact, just after one year, the bonded composite restoration had developed staining. She requested a more durable solution; specifically,

bonded porcelain veneers. As an actress, she desired and required extremely accurate shade matching. As a result, it was suggested that the left maxillary central also be treated with a porcelain veneer for an absolute shade match, to which she agreed.

Historically, other cases like these have been too often treated with the traditional full-coverage crowns (Figures 7 and 8). For our patient, after minimally invasive supragingival preparations (Figure 10), impressions, temporization, and resin cementation (no fighting with bleeding gums) using Clearfil SE Protect (Kuraray America) and RelyX Veneer Cement (3M ESPE) was very predictable. The Noritake CZR Layered porcelain veneers (Kuraray America) by Burbank Dental Lab delivered here were predictably beautiful, and the gingival margins remained very healthy (Figure 11). In addition, our patient did not have to lose any more of her natural tooth to repair the damage than was absolutely necessary.

IN SUMMARY

Advances in dentistry continually enable our profession to better serve our patients to give them a healthier and more beautiful dentition. Choosing the right material for each specific case and using proper techniques are imperative in providing optimal quality and aesthetics.

Supragingival restorations are not only friendlier to the tissues; they also preserve tooth structure, ultimately increasing the longevity of the tooth. Whether a traditional or digital impression is being taken, supragingival margins are much easier to capture, and final restorations are hence more accurate. Provisional restorations with good margins are easier to make, and patients' soft tissues will be healthier when they return for cementation. Finally, cleaning cement is much easier when you can see the entire margin, eliminating the common problem of leaving small amounts of cement behind subgingivally to cause tissue problems. Also, any margins in need of touch-up can be finished easier, faster, and better.

By delivering quality, predictable, minimally invasive, highly aesthetic restorations that provide long-term service, patient and doctor satisfaction will be sure to increase. Bottom line? Considering more partial-coverage restorations that keep our margins supragingival will make us better dentists! ♦

References

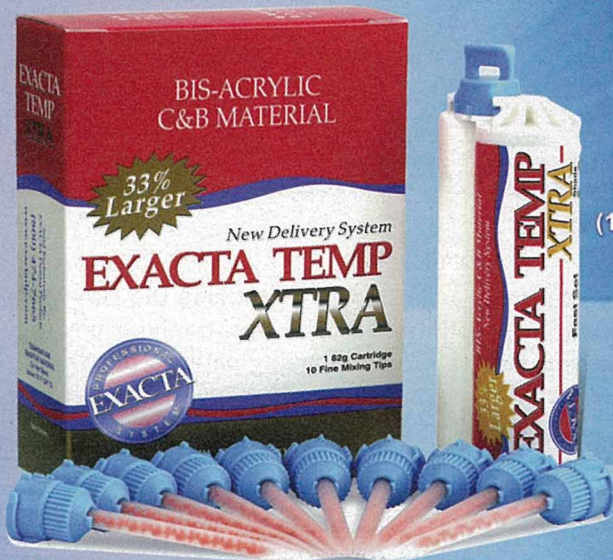1. Ruiz JL, Christensen GJ. Rationale for the utilization of bonded nonmetal onlays as an alternative to PFM crowns. *Dent Today*. 2006;25:80-83.
2. Ruiz JL, Christensen GJ, Sameni A, et al. Clinical performance of bonded ceramic and resin-based composite inlays and onlays using a self-etch bonding system: a 51-month report. *Inside Dentistry*. 2007;3:62-65.
3. Ruiz JL. Supragingival dentistry using metal-free restorations. *Dent Today*. 2008;27:104-109.
4. Christensen GJ. Are tooth-colored onlays viable alternatives to crowns? *CLINICIANS REPORT*. January 2012;5(1):1.3.
5. Christensen GJ. The state of fixed prosthodontic impressions: room for improvement. *J Am Dent Assoc*. 2005;136:343-346.
6. Shor A, Nicholls JI, Phillips KM, et al. Fatigue load of teeth restored with bonded direct composite and indirect ceramic inlays in MOD class II cavity preparations. *Int J Prosthodont*. 2003;16:64-69.
7. Santos MJ, Bezerra RB. Fracture resistance of maxillary premolars restored with direct and indirect adhesive techniques. *J Can Dent Assoc*. 2005;71:585.

Dr. Ruiz is course director of the University of Southern California (USC) Advanced Esthetic Dentistry Continuum and clinical instructor at USC. He is an associate instructor and mentor at PCC Utah, teaching with Dr. Gordon Christensen, and an independent evaluator of dental products for CLINICIANS REPORT. He is a Fellow of the AGD and practices general dentistry in the Studio District of Los Angeles. He lectures both internationally on aesthetic dentistry and leadership. He can be reached at (818) 558-4332 or via e-mail at ruiz@drruiz.com.


Dr. Kurtz is on faculty at the Los Angeles Institute of Clinical Dentistry, an instructor at the University of Connecticut Dental School, and maintains a private practice in Cheshire, Conn. She is past course director and a clinical instructor at the University of Southern California School of Dentistry. She received her doctorate in dentistry from Tufts University School of Dental Medicine. She can be reached at (203) 699-9705 or via e-mail at rkp701@gmail.com.

Disclosure: The authors report no disclosures.

The best value in dentistry just got better



\$116.95 per Kit
(1 82g cartridge & 10 small mixing tips)



New smaller mixing tips reduce waste

30%

EXACTA
Dental Direct
(800) 474-7665
www.exactadental.com

BUY DIRECT CALL 800-474-7665 or circle 82 on card